

See discussions, stats, and author profiles for this publication at: <https://www.researchgate.net/publication/229074284>

Nonextraction treatment of a Class II open bite in an adult patient

Article in *Journal of clinical orthodontics: JCO* · June 2012

Source: PubMed

CITATION

1

READS

277

1 author:



[Hector Luis Rodríguez](#)

Universidad Nacional Pedro Henríquez Ureña

4 PUBLICATIONS 5 CITATIONS

SEE PROFILE

Some of the authors of this publication are also working on these related projects:



Two phase Class II malocclusions treated with the Motion Appliance. [View project](#)

CASE REPORT

Nonextraction Treatment of a Class II Open Bite in an Adult Patient

HECTOR LUIS RODRÍGUEZ, DDS

Open bite is one of the most difficult orthodontic problems to treat—especially in adult patients, who frequently require orthognathic surgery.¹ Less invasive approaches, such as the use of skeletal anchorage for molar intrusion, have been introduced in recent years.²

Molar-distalization devices that can correct the underlying Class II malocclusion without extractions include the Pendulum appliance,³ repelling magnets,⁴ the Distal Jet,⁵ and many others. The Invisalign* system has been successful in treating some Class II conditions, but anteroposterior discrepancies are difficult to re-

solve with aligners.⁶

This article describes a case in which the Carriere Distalizer**⁷ was used for simultaneous correction of an open bite and a Class II relationship in the first phase of treatment, leaving the dental situation to be addressed with Invisalign in the second phase.

Diagnosis and Treatment Plan

A 27-year-old male presented with a Class II subdivision malocclusion, a 3mm open bite, and an upper midline deviation of 1mm to the right side (Fig. 1). Cephalometric analysis indicated that the open bite was not related to skeletal discrepancies, but was mainly a dental malocclusion. The profile view showed a straight nasolabial angle and a normal neck-chin length. The panoramic radiograph confirmed the presence of all permanent teeth except the upper and lower right third molars, which had been previously removed.

A two-phase treatment plan was designed in which a unilateral Carriere Distalizer would be

used initially to correct the Class II molar relationship. Since the patient preferred an esthetic option, the second phase would consist of Invisalign therapy.

Treatment Progress

Following extraction of the remaining two third molars, a passive .036" lower lingual arch was placed as anchorage, and a 27mm Carriere Distalizer was bonded in the maxilla from the left canine to the left first molar. Unilateral Class II elastics were prescribed for full-time wear, except while eating.

After six months of Distalizer treatment, a Class I molar and canine relationship had been obtained, the open bite had been corrected, and only minor dental discrepancies remained to be corrected during the second phase (Fig. 2).

Upper and lower impressions were taken for Invisalign, and Clincheck* projections were developed (Fig. 3). The patient

*Registered trademark of Align Technology, Inc., Santa Clara, CA; www.aligntech.com.

**Trademark of Ortho Organizers, Inc., Carlsbad, CA; www.orthoorganizers.com.



Dr. Rodríguez is Professor and Coordinator, Department of Orthodontics, Escuela Odontología, Universidad Nacional Pedro Henríquez Ureña, Santo Domingo, Dominican Republic; e-mail: ortoplan@claro.net.do.

Nonextraction Treatment of a Class II Open Bite in an Adult Patient _____

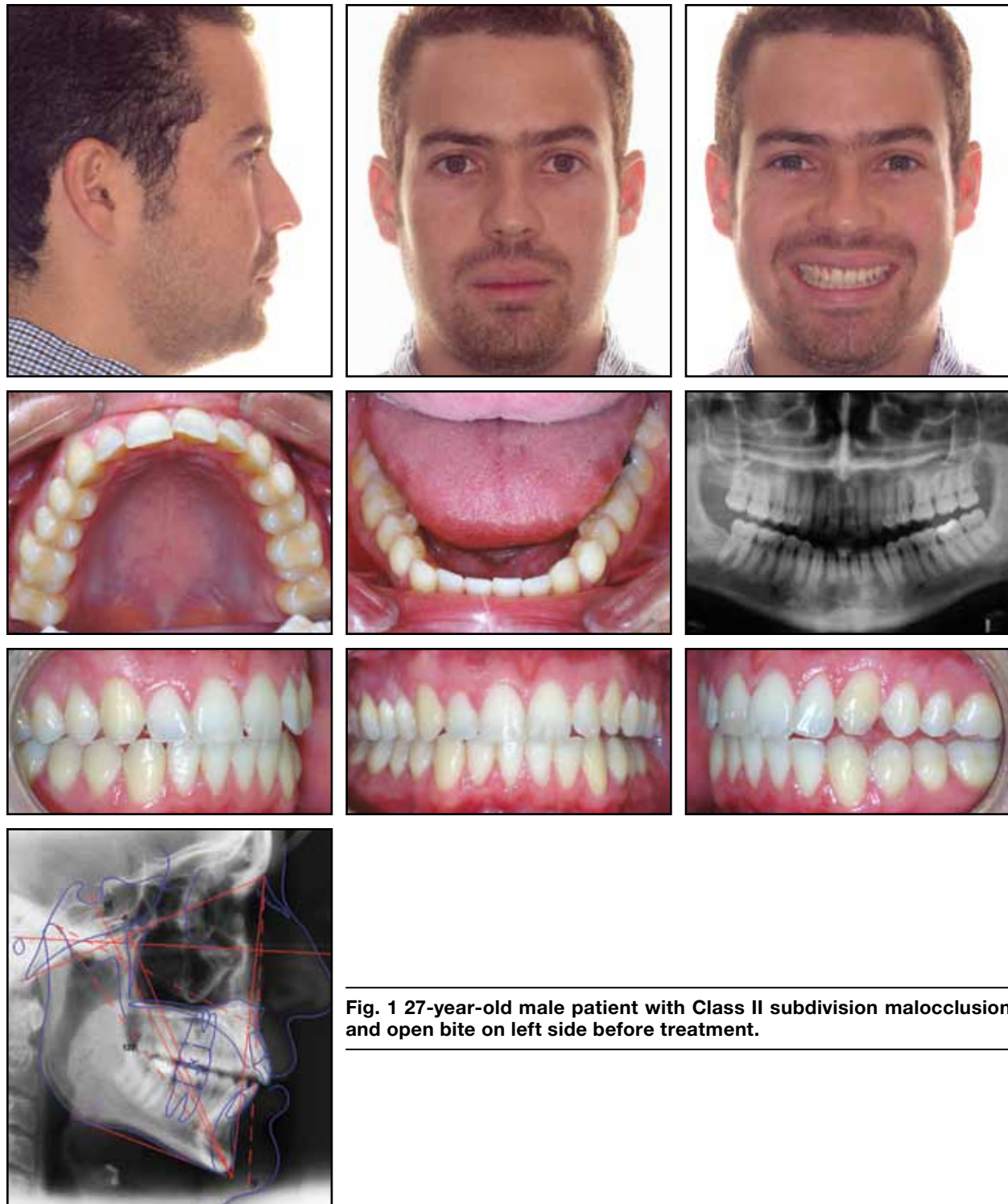


Fig. 1 27-year-old male patient with Class II subdivision malocclusion and open bite on left side before treatment.

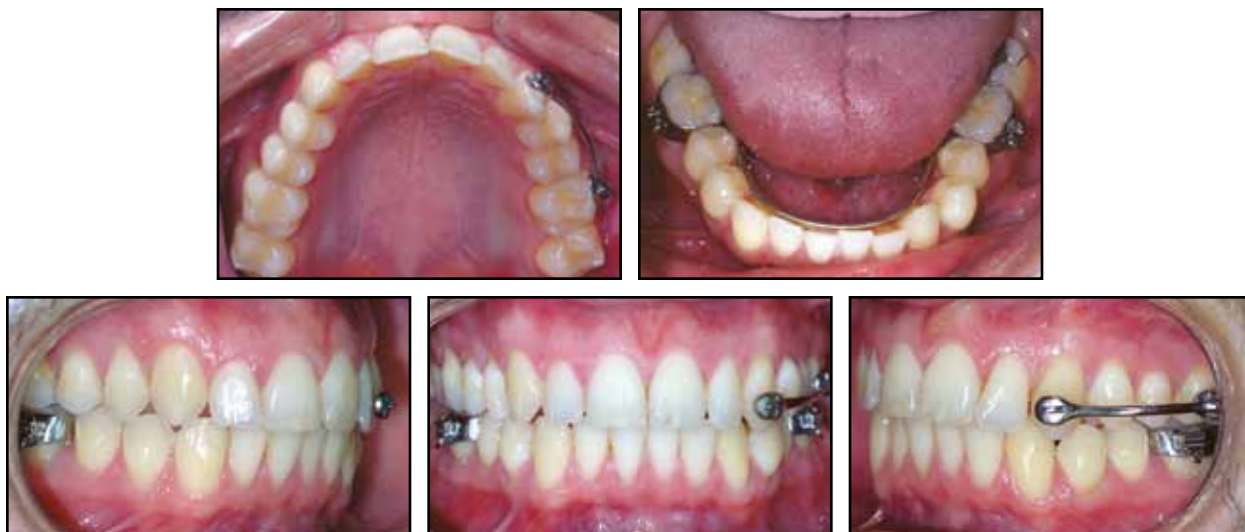

Fig. 2 After six months of treatment with unilateral Carriere Distalizer.

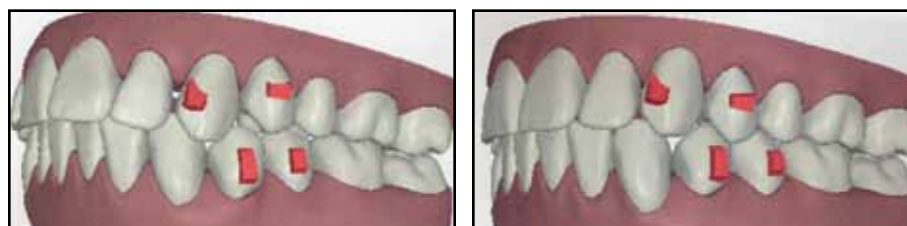

Fig. 3 Clincheck* projections for second phase of treatment.

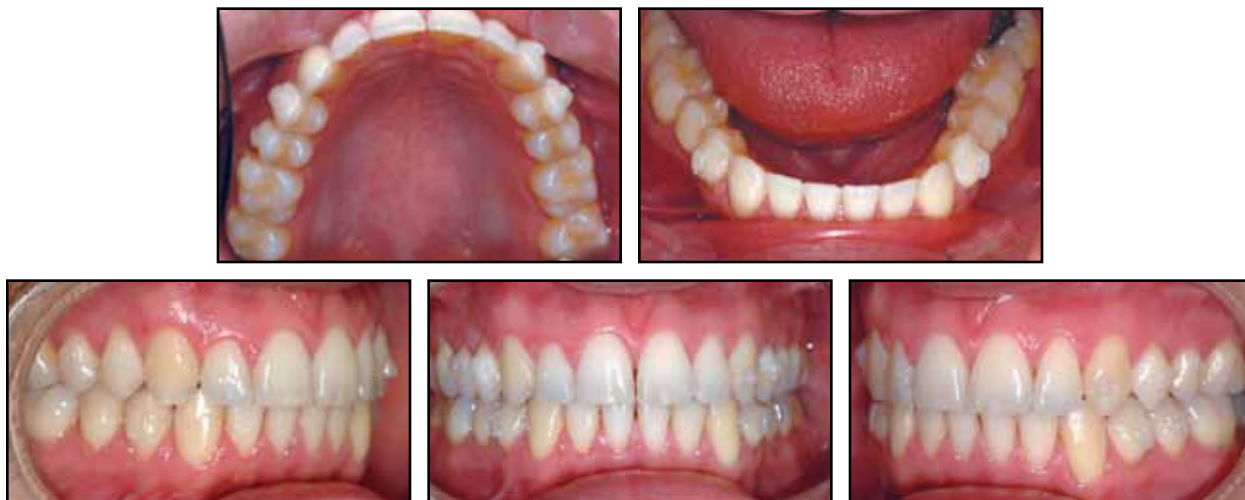

Fig. 4 Progress after four months of Invisalign* treatment.

Nonextraction Treatment of a Class II Open Bite in an Adult Patient

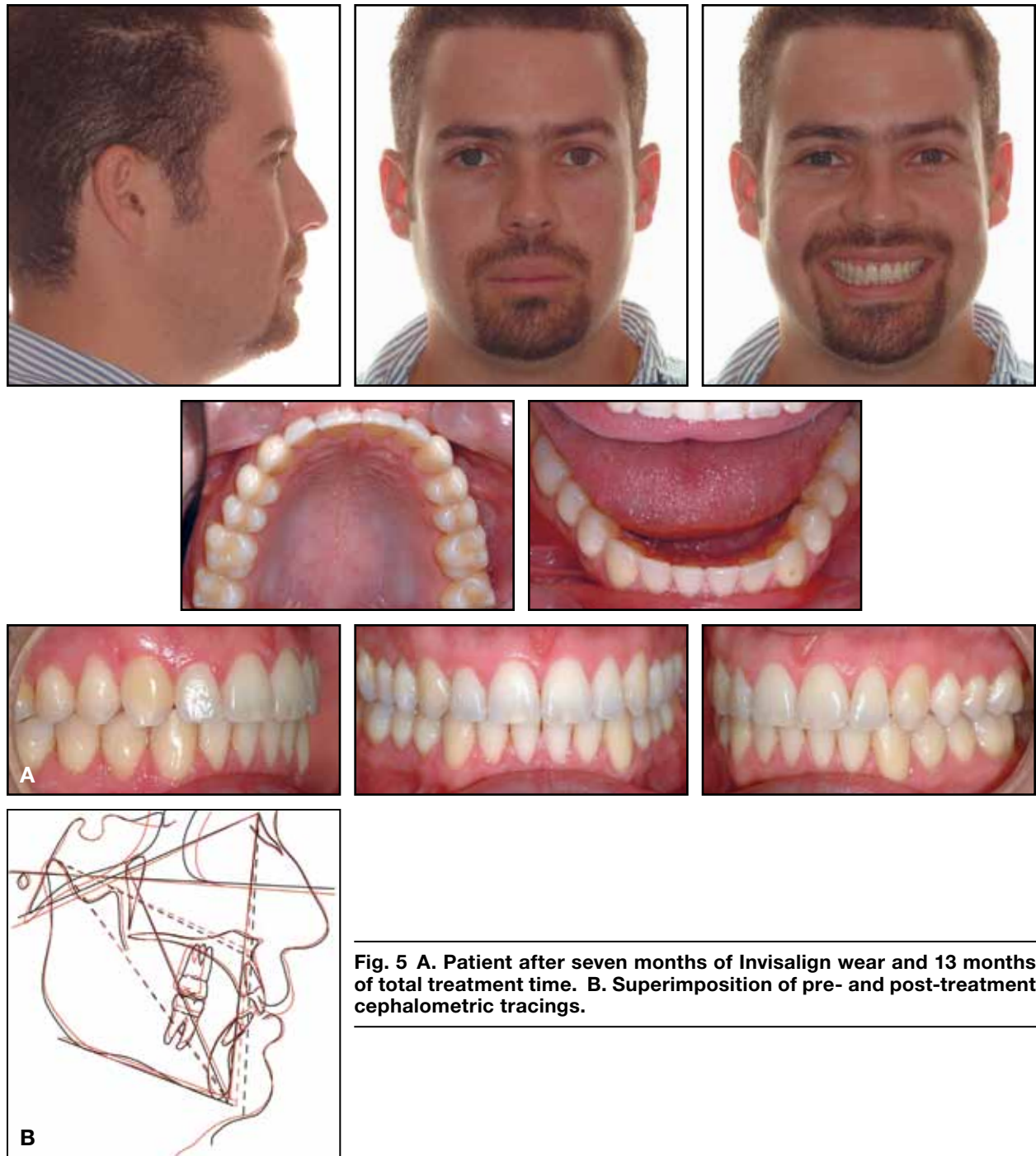


Fig. 5 A. Patient after seven months of Invisalign wear and 13 months of total treatment time. **B.** Superimposition of pre- and post-treatment cephalometric tracings.

wore the sequential aligners (Fig. 4), including a set of refinement aligners, for seven months.

After a total 13 months of treatment, the patient exhibited a solid Class I occlusion, a good vertical relationship, and a centered midline (Fig. 5).

Discussion

In the first phase of treatment, the Distalizer derotated the upper left first molar around its palatal root (Fig. 6)—an advantage of this system over other distalization methods—to correct the unilateral Class II relationship and open bite. Lower anchorage

was esthetically provided by a simple lingual arch; a lower Essix retainer can also be used in a patient who can be trusted to wear it full-time.

The combination of a unilateral Carriere Distalizer and Invisalign proved to be an excellent choice in this case. The patient was happy to comply with a plan that did not require the use of traditional braces. Overall, this approach shortened treatment considerably compared to fixed appliances or Invisalign alone.

REFERENCES

1. Speidel, T.M.; Isaacson, R.J.; and Worms, F.W.: Tongue-thrust therapy and anterior openbite: A review of new facial growth data, *Am. J. Orthod.* 62:287-295, 1972.
2. Park, Y.C.; Lee, H.A.; Choi, N.C.; and Kim, D.H.: Open bite correction by intrusion of posterior teeth with mini-screws, *Angle Orthod.* 78:699-710, 2008.
3. Hilgers, J.: The Pendulum appliance for Class II non-compliance therapy, *J. Clin. Orthod.* 26:706-714, 1992.
4. Gianelly, A.A.; Bonds, P.W.; and Johnson, W.M.: Distalization of molars with repelling magnets, *J. Clin. Orthod.* 22:40-44, 1988.
5. Carano, A. and Testa, M.: The Distal Jet for upper molar distalization, *J. Clin. Orthod.* 30:374-380, 1996.
6. Schupp, W.; Haubrich, J.; and Neumann, I.: Class II Correction with the Invisalign system, *J. Clin. Orthod.* 44:28-35, 2010.
7. Rodríguez, H.: Unilateral application of the Carriere Distalizer, *J. Clin. Orthod.* 45:177-180, 2011.

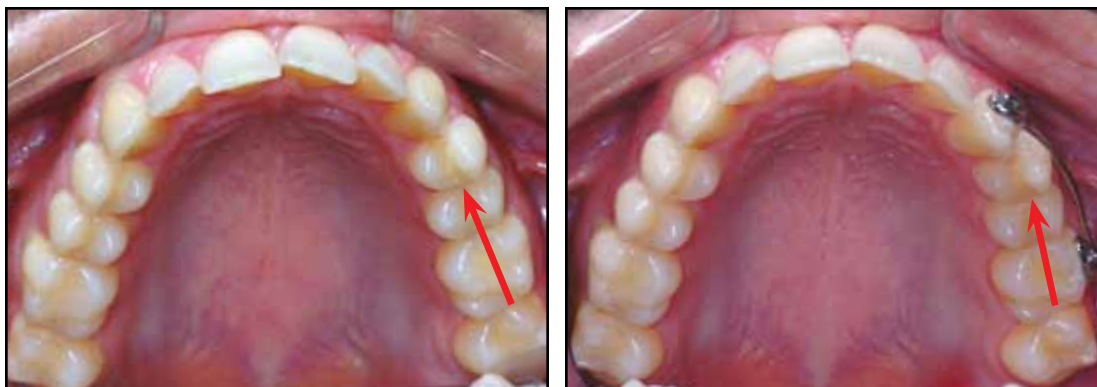


Fig. 6 Before and after six months of Carriere Distalizer treatment, showing derotation of upper left first molar around its palatal root.